

LETTER TO THE EDITOR

Open Access

The “wireless” portion of a wire-reinforced endotracheal tube may kink



Takuhiko Wakamatsu* and Hisanari Ishii

To the Editor,

Wire-reinforced endotracheal tubes (WRETs) have a layered structure in which metal wire is embedded in the wall of the tube shaft. This structure makes the tube resistant to kinking caused by angulated forces and improves patient safety [1]. WRETs are useful for head and neck surgery during which kinking of the tube is likely to occur [2]. However, the use of a WRET may be associated with several problems causing the partial or total occlusion of the tube. There are numerous reports of obstruction of WRETs due to dissection of the layered structure [3, 4], patient bite [2, 5], or compression by surgical devices [1]. We herein report a very rare case in which a WRET became kinked and obstructed at its “wireless” portion.

A 74-year-old, 148-cm, 57-kg female patient underwent neck lymph node resection under general anesthesia. A WRET of 7.0 mm in internal diameter (Parker Flex-Tip PFRC tracheal tube, Parker medical, CO, USA) was placed orally. Volume-controlled mechanical ventilation was performed with a tidal volume of 450 ml and a respiratory rate of 10 breaths per minute. The neck of the patient was extended, and the respiratory circuit was fixed with a flexible circuit holder (ACOMA, Japan). After covering the patient’s head with surgical drapes, the surgical procedure was started. During the procedure, the surgeon moved the circuit holder to improve his working space. Subsequently, the peak airway pressure gradually increased from 16 cmH₂O to a maximum of 28 cmH₂O without a marked change in the waveform of capnography, increase in end-tidal CO₂, or decrease in SpO₂. The tidal volume setting was reduced from 450 to 390 ml, which resulted in

a decrease in the peak airway pressure to 18 cmH₂O. The surgical procedure was not aborted and was finished uneventfully. After the removal of the surgical drapes, kinking of the tube causing obstruction was observed (Fig. 1). The patient recovered from general anesthesia without complications.

In certain types of WRETs, there is a “wireless” portion of a few millimeters between the end of the embedded coiled wire in the tube and the tip of the plastic slip joint (Fig. 2a). Kinking occurs when an angulated force is applied at this “wireless” portion (Fig. 2b). We measured the length of the “wireless” portion in Parker Flex-Tip PFRC tracheal tubes of 7.0 mm in internal diameter. We chose 10 tubes randomly from the stock in our hospital. The length of the “wireless” portion ranged from 0.4 to 2.1 mm. In our case, the length of the “wireless” portion was 1.7 mm, which was within the range for this type of tube. Moreover, the tube kinked with an angulated force that was not applied directly to the tube.

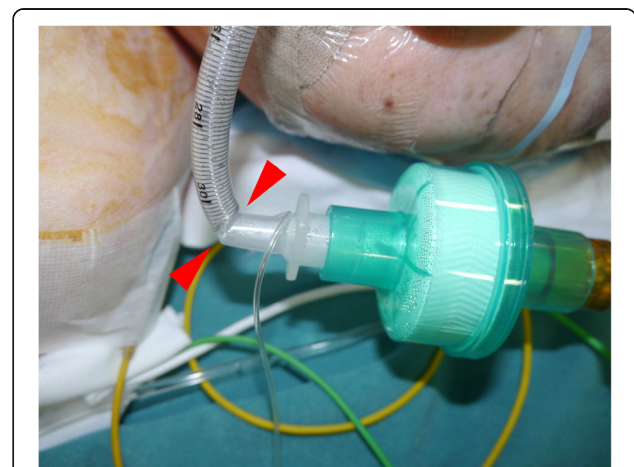


Fig. 1 Kinking of the WRET after surgery. The WRET kinked at the portion between the end of the embedded coiled wire in the tube and the tip of the plastic slip joint (red arrowheads)

* Correspondence: twaka@tenriyorozu.jp
Department of Anesthesia, Tenri Hospital, Mishima-cho 200, Tenri, Nara 632-8552, Japan

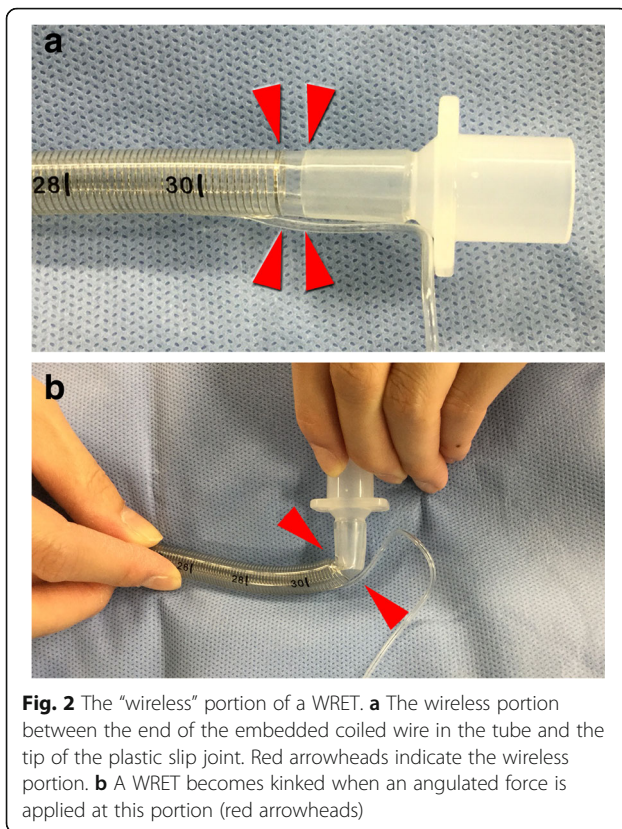


Fig. 2 The “wireless” portion of a WRET. **a** The wireless portion between the end of the embedded coiled wire in the tube and the tip of the plastic slip joint. Red arrowheads indicate the wireless portion. **b** A WRET becomes kinked when an angulated force is applied at this portion (red arrowheads)

Thus, kinking of WRETs may occur in clinical situations.

Certain types of WRETs have a “wireless” portion that potentially causes kinking of the tube. The endotracheal tube must be kept at an adequate angle to avoid kinking, even when using a wire-reinforced tube.

Abbreviation

WRET: Wire-reinforced endotracheal tube

Acknowledgements

Not applicable.

Funding

None.

Availability of data and materials

Not applicable.

Authors' contributions

TW was the primary anesthesiologist and drafted the manuscript. HI helped to draft the manuscript. Both authors read and approved the final manuscript.

Ethics approval and consent to participate

Not applicable.

Consent for publication

Written informed consent was obtained from the patient.

Competing interests

The authors declare that they have no competing interests.

Publisher's Note

Springer Nature remains neutral with regard to jurisdictional claims in published maps and institutional affiliations.

Received: 23 January 2019 Accepted: 27 February 2019

Published online: 16 March 2019

References

1. Hosseinzadeh N, Samadi S, Jafari Javid M, Takzare A. Impending complete airway obstruction from a reinforced orotracheal tube: a case report. *Acta Med Iran.* 2015;53:590–2.
2. Eipe N, Choudhrie A, Pillai AD, Choudhrie R. Neck contracture release and reinforced tracheal tube obstruction. *Anesth Analg.* 2006;102:1911–2.
3. Rao GS, Ali Z, Ramkiran S, Chandrasekhar HS. The dissection of a reinforced endotracheal tube causing near-fatal intraoperative airway obstruction. *Anesth Analg.* 2006;103:1624–5.
4. Itani O, Mallat C, Jazzar M, Hammoud R, Shaaban J. Obstruction of a non-sterilized reinforced endotracheal tube during craniotomy under general anesthesia. *Anesth Essays Res.* 2015;9:260–2.
5. Ball JE, Platt S. Obstruction of a reinforced oral tracheal tube. *Br J Anaesth.* 2010;105:699–700.

Submit your manuscript to a SpringerOpen[®] journal and benefit from:

- Convenient online submission
- Rigorous peer review
- Open access: articles freely available online
- High visibility within the field
- Retaining the copyright to your article

Submit your next manuscript at ► [springeropen.com](https://www.springeropen.com)