

CASE REPORT

Open Access



Successful clavicle fracture surgery performed under selective supraclavicular nerve block using the new subclavian approach

Hironobu Ueshima* and Hiroshi Otake

Abstract

Objectives: Cervical nerves block cannot be performed on some patients because of the risk of phrenic nerve paralysis. To overcome this limitation, we discovered the site of selective only supraclavicular nerve block at the subclavian site.

Case report: We present the case of a 62-year-old woman with clavicular fracture. We performed a selective block of the supraclavicular nerve and the fifth and sixth cervical nerves for the clavicle fracture surgery.

Conclusions: We can perform selective supraclavicular nerve blocks for clavicular fracture surgery of patients who have bilateral pneumothorax.

Keywords: Clavicular fracture, Selective only supraclavicular nerve block, Cervical plexus nerve block

Background

Occasionally, patients with clavicle fractures also have a pneumothorax. If we induce regional anesthesia without general anesthesia for clavicle fracture surgery, we must relieve the pain of the supraclavicular nerve and the fifth and the sixth cervical nerves (C5 and C6) [1]. A cervical plexus nerve block is usually performed to anesthetize the supraclavicular nerve. In this case, we performed a selective supraclavicular nerve block instead of a cervical plexus nerve block. There have been no reports in literature on the use of a selective supraclavicular nerve block at the subclavian site.

Case presentation

A 62-year-old woman (height, 155 cm; weight, 45 kg), with a fracture of the left clavicle due to a traffic accident, was scheduled to undergo open reduction and internal fixation. She had bilateral pneumothorax and was equipped with chest drains in the bilateral thoracic cavity. In addition, she had been undergoing

artificial dialysis for 10 years because of severe renal dysfunction. Considering the potential complications of general anesthesia, we decided to induce only regional anesthesia without general anesthesia.

We had to relieve the pain of the supraclavicular nerve and the fifth and sixth cervical nerves (C5 and C6) for the left clavicle fracture surgery. The most appropriate methods include both a left cervical plexus nerve block and a brachial plexus nerve block. However, since the cervical plexus nerve block is associated with a risk of phrenic nerve paralysis, we opted for a selective supraclavicular nerve block.

In the operating room, the patient was connected to several monitors. We performed the selective C5 and C6 blocks by injecting 0.75 % levobupivacaine (10 mL) around the C5 and C6 between the anterior and middle scalene muscles using a high-frequency linear probe of a LOGIQ e Premium system (GE Healthcare Japan, Tokyo, Japan). After these injections, we confirmed that the local anesthetic did not spread around the fourth, seventh, and eighth nerves by using the LOGIQ e Premium system.

* Correspondence: ueshimhi@yahoo.co.jp

Department of Anesthesiology, Showa University Hospital, Hatanodai Shinagawa-ku, Tokyo, Japan

The selective supraclavicular nerve block was administered by injecting 0.75 % levobupivacaine (10 mL) from the head side into the space beyond the pectoralis major muscle that was 2 cm lateral to the left sternal edge by means of the high-frequency linear probe (Figs. 1 and 2). Twenty minutes after applying the blocks with a pin-prick test, the breast resection was performed without using any sedative. The perioperative course was uneventful and did not require additional analgesics. There were no changes caused phrenic nerve paralysis on the postoperative chest X-rays.

Discussion

Prior to this case, there have been no reports in literature on the use of a selective supraclavicular nerve block at the subclavian site. Hence, we mainly performed the cervical plexus nerve block to anesthetize the selective supraclavicular nerve. However, as the cervical plexus nerve block may lead to phrenic nerve paralysis, it cannot be performed in patients with bilateral pneumothorax.

The supraclavicular nerve arises from the third and fourth cervical nerves and emerges beneath the posterior border of the sternocleidomastoid muscle. The supraclavicular nerve branches into the medial, intermediate, and lateral supraclavicular nerves at the sternocleidomastoid and descends into the posterior triangle of the neck beneath the platysma and deep cervical fascia (Fig. 3) [2]. These branches run parallel beyond the pectoralis major muscle. In this case, we selectively blocked the supraclavicular nerve by injecting local anesthetic at the site of the pectoralis major muscle. The selective supraclavicular nerve block reported by Valdés-Vilches and Sánchez-del Águila [3] is performed via the supraclavicular approach and has the risk of phrenic nerve block if more than required volumes are injected.

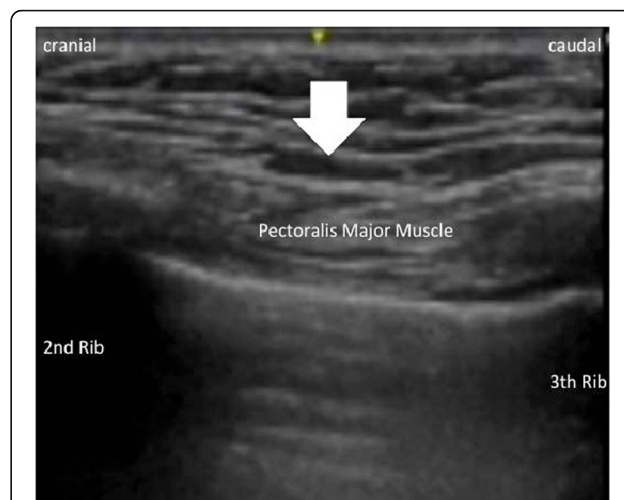

Fig. 2 An ultrasound image of the selective supraclavicular nerve block. An injection point is a white arrow

Administering a nerve block at the site of the pectoralis major muscle enables the procedure to be performed safely and easily. In addition, we may be able to use this approach for performing selective supraclavicular nerve block in patients with severe complications such as bilateral pneumothorax and hemorrhagic diathesis. In the future, we may be able to perform selective supraclavicular nerve block for perioperative analgesia of patients with such complication. For example, the nerve block may be used effectively in surgeries for clavicle fracture and anterior rib fractures.

There have been no reports in the literature on the use of selective supraclavicular nerve block in clavicle fractures. Therefore, it is uncertain whether adequate anesthetic volumes and concentration would achieve a satisfactory result. In particular, administering a small volume at the site may not be able to block lateral supraclavicular nerves.

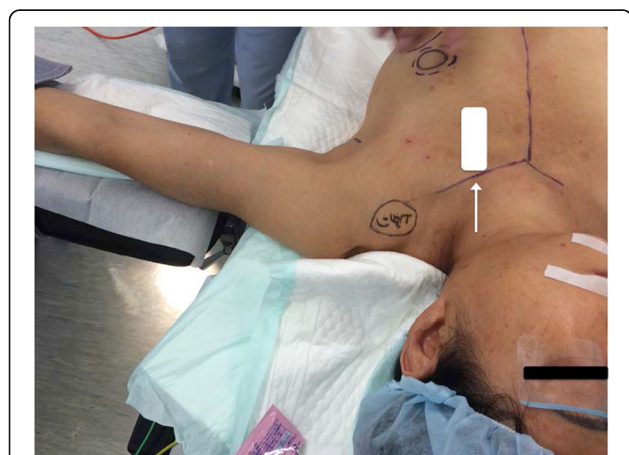

Fig. 1 Probe's method. A probe is a white box, and the injection site is a white arrow

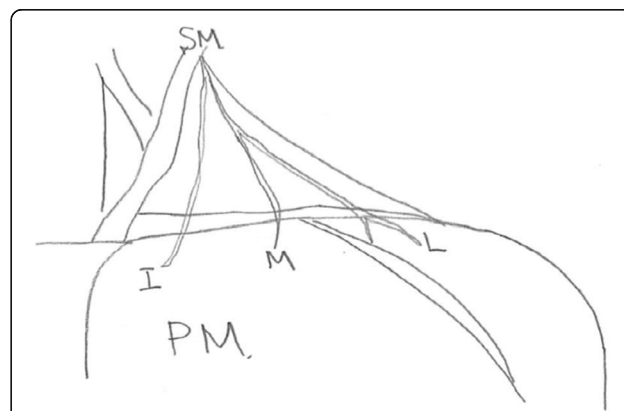


Fig. 3 An illustration of the supraclavicular nerve. SM sternocleidomastoid muscle, PM pectoralis major muscle, I intermediate, M medial, L lateral

In addition, there were no cadaver studies showing the spread of dye or something. Therefore, we must eventually perform some cadaver studies to confirm the spread.

Conclusions

We could perform a selective supraclavicular nerve block using the new subclavian approach instead of a cervical plexus nerve block.

Acknowledgements

None.

Funding

None.

Authors' contributions

HU is responsible for the study design/planning and wrote the paper. HU and HO revised the paper. Both authors read and approved the final manuscript.

Competing interests

The authors declare that they have no competing interests.

Consent for publication

Consents for publication were gained.

Received: 30 August 2016 Accepted: 4 November 2016

Published online: 08 November 2016

References

1. Tran DQ, Tiyaprasertkul W, González AP. Analgesia for clavicular fracture and surgery: a call for evidence. *Reg Anesth Pain Med.* 2013;38:539–43.
2. Tubbs RS, Salter EG, Oakes WJ. Anomaly of the supraclavicular nerve: case report and review of the literature. *Clin Anat.* 2006;19:599–601.
3. Valdés-Vilches LF, Sánchez-del Águila MJ. Anesthesia for clavicular fracture: selective supraclavicular nerve block is the key. *Reg Anesth Pain Med.* 2014;39:258–9.

Submit your manuscript to a SpringerOpen[®] journal and benefit from:

- Convenient online submission
- Rigorous peer review
- Immediate publication on acceptance
- Open access: articles freely available online
- High visibility within the field
- Retaining the copyright to your article

Submit your next manuscript at ► springeropen.com
