

CASE REPORT

Open Access



# Downfolding of the epiglottis into the laryngeal inlet after tracheal intubation using the McGRATH™ MAC videolaryngoscope: a case report

Haruno Soma<sup>1</sup>, Kenta Furutani<sup>1\*</sup> , Ayaka Hibino<sup>2</sup>, Akinobu Hibino<sup>2</sup> and Hiroshi Baba<sup>1</sup>

## Abstract

**Background:** Downfolding of the epiglottis into the laryngeal inlet is considered to be a rare complication of tracheal intubation. We describe a case of epiglottic downfolding during tracheal intubation using a McGrath videolaryngoscope (McGRATH™ MAC).

**Case presentation:** A 44-year-old female was scheduled for breast reconstruction surgery. Intubation was performed using a McGrath videolaryngoscope. After intubation, videolaryngoscopy revealed that the epiglottis was inverted and folded down into the laryngeal inlet. We elevated the larynx anteriorly using the McGrath videolaryngoscope, enabling the downfolded epiglottis to be pulled out from the laryngeal inlet and restored to its original position. After surgery, the patient was extubated without any complications.

**Conclusions:** When using the McGrath videolaryngoscope, both glottic exposure similar to that achieved with the Macintosh laryngoscope and careful observation of the epiglottis should enable the prevention, detection, and treatment of epiglottic downfolding into the laryngeal inlet.

**Keywords:** McGRATH™ MAC, Videolaryngoscope, Tracheal intubation, Epiglottic downfolding, Epiglottis, Laryngeal inlet

## Background

Downfolding of the epiglottis into the laryngeal inlet is a rare complication of tracheal intubation. Prolonged downfolding may result in swelling of the epiglottis after extubation although no reports have described severe airway obstruction caused by epiglottic downfolding.

Epiglottic downfolding into the laryngeal inlet has been reported during or after tracheal intubation using the Macintosh laryngoscope [1, 2], the intubating laryngeal mask airway [3], a fiberscope [4], and lighted stylets [5, 6]. Downfolding of the epiglottis has also been reported when using a rigid indirect videolaryngoscope,

the Pentax Airway Scope (Pentax-AWS®; Hoya Corporation, Tokyo, Japan) [7]. Two cases of epiglottis malposition were identified in this report; the authors suggest that the prolapse may not have been visible on the Pentax-AWS screen because the positioning of the camera means that the tip of the blade can impede the view of the epiglottis.

The McGrath videolaryngoscope (McGRATH™ MAC; Airclaf Medical Ltd, Edinburgh, UK) has been widely used both for patients with normal airways and those who are difficult to intubate. Although the manufacturer's recommendation is that the tip of the blade should be placed in the vallecula, as for the Macintosh laryngoscope, it is also possible to elevate the epiglottis directly if necessary. To our knowledge, there are currently no published reports of the epiglottis downfolding

\* Correspondence: [kenta-f@med.niigata-u.ac.jp](mailto:kenta-f@med.niigata-u.ac.jp)

<sup>1</sup>Department of Anesthesiology, Niigata University Medical and Dental Hospital, 1-754 Asahimachi-dori, Chuo-ku, Niigata 951-8520, Japan  
Full list of author information is available at the end of the article

into the laryngeal inlet when using the McGrath videolaryngoscope. Here, we describe a case of epiglottic downfolding during tracheal intubation using the McGrath videolaryngoscope.

### Case presentation

Written informed consent was obtained from the patient for publication of this case report and accompanying images. In our institution, case reports are exempted from IRB approval.

A 44-year-old female (height 151.5 cm, weight 49.5 kg) was scheduled for breast reconstruction surgery using a pedicled flap of the latissimus dorsi muscle. Although the patient did not present any complication in her airway during the preoperative evaluation, the anesthesia record of her previous mastectomy procedure stated that tracheal intubation was performed using a McGrath videolaryngoscope due to difficulties using a Macintosh laryngoscope. Therefore, we planned to use a McGrath videolaryngoscope as the first choice to enable a smooth intubation.

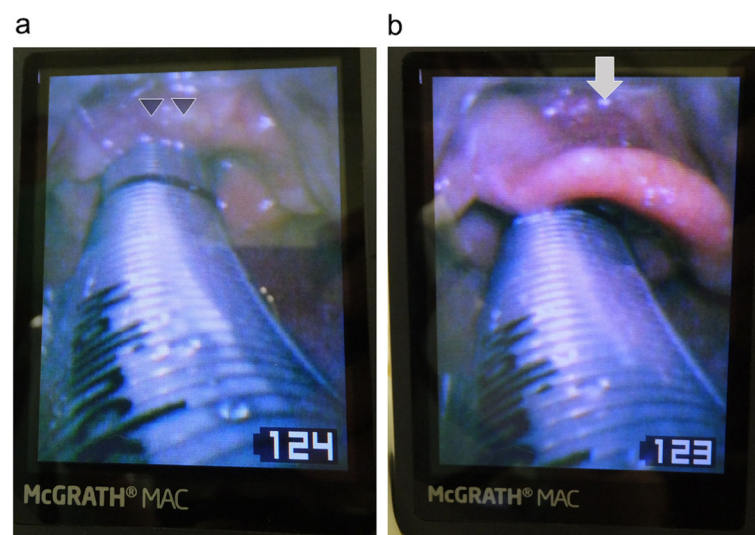
General anesthesia was induced and maintained with a continuous infusion of propofol (3.0 µg/ml, target controlled infusion) combined with remifentanyl (0.4 µg/kg/min). Rocuronium bromide (40 mg) was administered intravenously to facilitate tracheal intubation. Neuromuscular monitoring was not used because it was not available at that time. After mask ventilation, intubation was easily performed by an anesthesia resident using a McGrath videolaryngoscope. The resident had experienced approximately 10 cases of tracheal intubation using this device. However, the supervising anesthesiologist who specialized

in difficult airway management suspected that the epiglottis had been inverted by the blade of the McGrath videolaryngoscope and pushed into the laryngeal inlet. After fixation of the endotracheal tube, the supervising anesthesiologist attempted to gain a detailed view of the condition of the epiglottis using McGrath videolaryngoscopy. It was established that the epiglottis was prolapsed; it had been pushed into the laryngeal inlet along with the endotracheal tube (Fig. 1a).

Although we believed that the problem would be easily solved by extubation, we discussed another solution because her subsequent intubation might have proved to be difficult even though the initial intubation had been easy to achieve. Firstly, we attempted to elevate the larynx in an anterior direction using the McGrath videolaryngoscope aiming to restore the epiglottis to its normal position by widening the laryngeal space. We inserted the tip of the McGrath blade carefully into the vallecula. When the larynx was elevated anteriorly, we were fortunately able to pull the downfolded epiglottis out from the laryngeal inlet and restored it to its original position (Fig. 1b). We observed only a little submucosal hemorrhage on the surface of the epiglottis and no swelling. Approximately 8 h after the surgery, the patient was extubated smoothly without respiratory symptoms. No postoperative complications were observed except for slight hoarseness.

### Discussion

This case report suggests that downfolding of the epiglottis into the laryngeal inlet can occur during tracheal



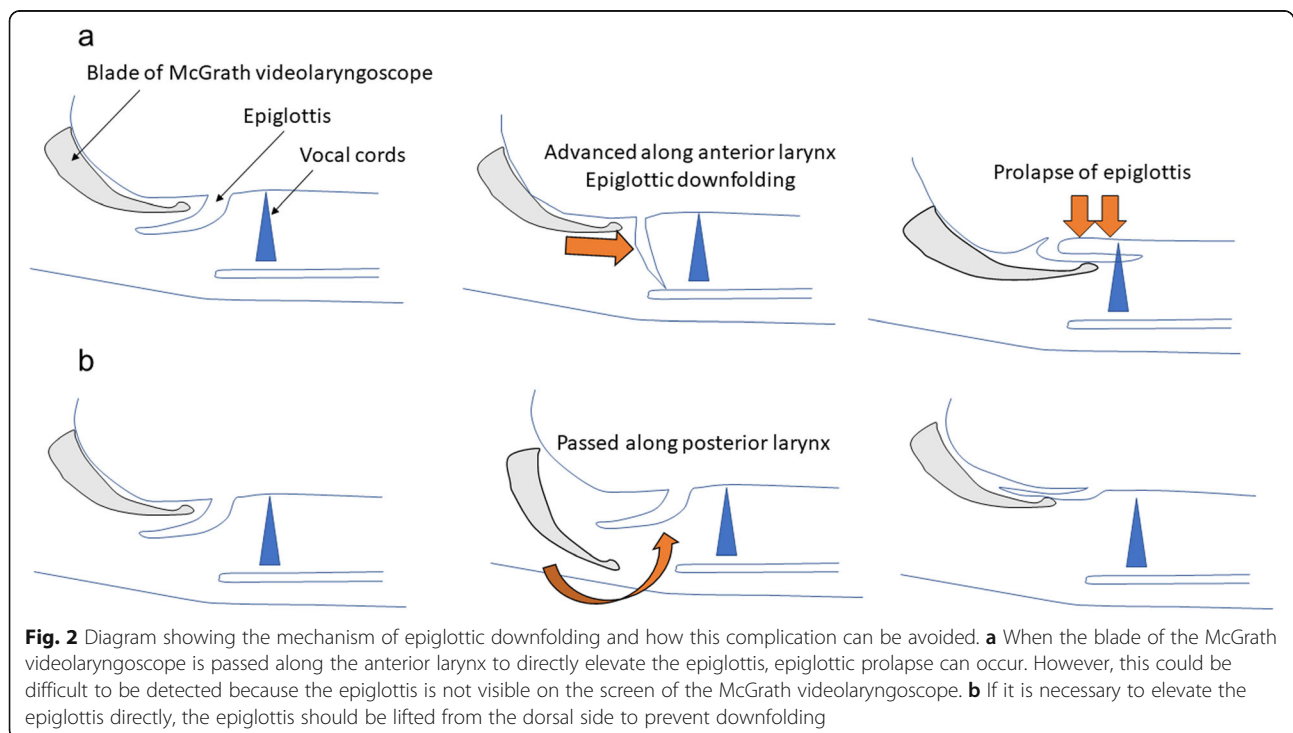
**Fig. 1** Views of the larynx as seen on the screen of the McGrath videolaryngoscope. **a** After tracheal intubation, the epiglottis (arrowheads) is prolapsed and folded down into the laryngeal inlet. **b** The epiglottis has been restored to its original position by gentle glottic exposure with the McGrath videolaryngoscope blade. Only slight submucosal hemorrhage can be observed on the surface of the epiglottis (arrow), and swelling has not occurred

intubation when using the McGrath videolaryngoscope and that the downfolded epiglottis can be restored to its original position by gentle glottic exposure using the McGrath blade. Epiglottic downfolding into the laryngeal inlet has been considered to be a rare complication of tracheal intubation [7]. However, as anesthesiologists rarely observe the larynx after tracheal intubation, this prolapse may occur much more frequently than it was currently thought. Although there are fortunately no reports of severe complications associated with the downfolding of the epiglottis, prolonged prolapse of the epiglottis may cause swelling, resulting in airway obstruction [1]. Therefore, if possible, the position of the epiglottis should be carefully observed during tracheal intubation to reduce the risk of prolonged prolapse.

Epiglottic downfolding into the laryngeal inlet has been reported to be associated with blind intubation techniques such as supraglottic airway-guided intubation [3], fiberoptic intubation [4], and light-guided intubation [5, 6] because these techniques do not enable observation of the epiglottis during intubation. However, it can also occur using the Macintosh laryngoscope [1, 2] or the Pentax-AWS which provide better visualization [7]. A previous case series [7] reported that the rate of epiglottis prolapse with the Pentax-AWS was approximately three in 1000 intubations. In these cases, prolapse was caused by the blade of the Pentax-AWS as it passed along the anterior larynx. To prevent this complication, the authors recommended that the Pentax-AWS blade should be advanced along the posterior aspect of the airway as in the

laryngeal mask airway insertion technique [7]. Epiglottic downfolding into the laryngeal inlet when using the McGrath videolaryngoscope may be caused by the same mechanism as for the Pentax-AWS (Fig. 2a). Although the typical insertion technique for the McGrath videolaryngoscope differs from that of the AWS in that the tip of the blade is usually inserted into the vallecula, as for the Macintosh laryngoscope, the blade can also be used to elevate the epiglottis directly. When it is necessary to elevate the epiglottis directly, we recommend that the blade should be advanced along the posterior aspect of the airway; in other words, the epiglottis should be lifted from the dorsal side to prevent downfolding (Fig. 2b).

There are no established methods to correct epiglottis prolapse. In previous cases, the epiglottis has been restored to its original position using a McCoy-type laryngoscope [3], a fiberscope [4], endoscopic forceps [6], and partial extubation [1, 2, 5, 7]. In the present case report, the epiglottis prolapse was corrected easily by gentle glottic exposure using the McGrath videolaryngoscope without extubation or the use of any specialized devices. In this case, early detection was a possible reason for success. The problem was easily corrected because the epiglottis was still soft and elastic at the time of detection. If detection is delayed, the epiglottis can become edematous and, thus, more difficult to be restored. Therefore, whenever possible, anesthesiologists should carefully observe the condition of the epiglottis during and immediately after tracheal intubation using the McGrath videolaryngoscope.



In this report, we described a case of epiglottic downfolding into the laryngeal inlet after tracheal intubation using the McGrath videolaryngoscope. After the prolapse, we were able to restore the epiglottis to its original position by gentle glottic exposure using the McGrath videolaryngoscope without removal of the endotracheal tube. During tracheal intubation using the McGrath videolaryngoscope, Macintosh-type glottic exposure and careful observation of the epiglottis can enable the prevention and detection of epiglottis prolapse.

#### Abbreviations

McGrath: McGRATH™ MAC; Pentax-AWS: Pentax Airway Scope®

#### Acknowledgments

The authors would like to thank Editage for providing editorial assistance.

#### Authors' contributions

KF was the supervising anesthesiologist and prepared, drafted, revised, and edited the manuscript. HS drafted the manuscript and prepared the figures. Akinobu H and Ayaka H helped to edit the manuscript. HB provided supervision and edited the manuscript. The author(s) read and approved the final manuscript.

#### Authors' information

HS: M.D., Resident, Department of Anesthesiology, Niigata University Medical and Dental Hospital, Niigata, Japan

KF: M.D., Ph.D., Assistant Professor, Department of Anesthesiology, Niigata University Medical and Dental Hospital, Niigata, Japan

Akinobu H: M.D., Ph.D., Resident, Department of Anesthesiology, Niigata City General Hospital, Niigata, Japan

Ayaka H: M.D., Resident, Department of Anesthesiology, Niigata City General Hospital, Niigata, Japan

HB: M.D., Ph.D., Professor, Department of Anesthesiology, Niigata University Medical and Dental Hospital, Niigata, Japan

#### Funding

The authors declare that they have no external funding.

#### Availability of data and materials

Not applicable

#### Ethics approval and consent to participate

In our institution, case reports are exempted from IRB approval.

#### Consent for publication

Written informed consent was obtained from the patient for publication of this case report and any accompanying images.

#### Competing interests

The authors declare that they have no competing interests.

#### Author details

<sup>1</sup>Department of Anesthesiology, Niigata University Medical and Dental Hospital, 1-754 Asahimachi-dori, Chuo-ku, Niigata 951-8520, Japan.

<sup>2</sup>Department of Anesthesiology, Niigata City General Hospital, 463-7 Shumoku, Chuo-ku, Niigata 951-8550, Japan.

Received: 10 May 2020 Accepted: 27 May 2020

Published online: 05 June 2020

#### References

1. Lin TS, Chen CH, Yang MW. Folding of the epiglottis—an unusual complication to be recognized after laryngoscopic endotracheal intubation. *J Clin Anesth.* 2004;16:469–71.
2. Prakash S, Sitalakshmi N, Nayar P, Pawar M. Downfolding of the epiglottis during laryngoscopic tracheal intubation. *J Anaesthesiol Clin Pharmacol.* 2014;30:571–2.

3. Takenaka I, Aoyama K, Nagaoka E, Seto A, Nijima K, Kadoya T. Malposition of the epiglottis after tracheal intubation via the intubating laryngeal mask. *Br J Anaesth.* 1999;83:962–3.
4. Takenaka I, Aoyama K, Abe Y, Iwagaki T, Takenaka Y, Kadoya T. Malposition of the epiglottis associated with fiberoptic intubation. *J Clin Anesth.* 2009; 21:61–3.
5. Aoyama K, Takenaka I, Nagaoka E, Kadoya T, Sata T, Shigematsu A. Potential damage to the larynx associated with light-guided intubation: a case and series of fiberoptic examinations. *Anesthesiology.* 2001;94:165–7.
6. Ikegami N, Kikuchi A, Tamai S. Epiglottic prolapse induced by lighted stylet tracheal intubation. *J Anesth.* 2011;25:294–7.
7. Suzuki A, Katsumi N, Honda T, Sasakawa T, Kunisawa T, Henderson JJ, et al. Displacement of the epiglottis during intubation with the Pentax-AWS Airway Scope. *J Anesth.* 2010;24:124–7.

#### Publisher's Note

Springer Nature remains neutral with regard to jurisdictional claims in published maps and institutional affiliations.

Submit your manuscript to a SpringerOpen<sup>®</sup> journal and benefit from:

- Convenient online submission
- Rigorous peer review
- Open access: articles freely available online
- High visibility within the field
- Retaining the copyright to your article

Submit your next manuscript at ► [springeropen.com](https://www.springeropen.com)